

Treatment of Gingival Pigmentation with Er,Cr:YSGG Laser

G. Berk^a, K. Atici^b, N. Berk^c

^a Dentist in private practice, DENTA FORM, Ankara, Turkey.

^b Periodontologist in private practice, DENTA FORM, Ankara, Turkey.

^c Orthodontist in private practice, DENTA FORM, Ankara, Turkey.

Purpose: Melanin hyperpigmented gingiva is an esthetic problem in many individuals, particularly if the hyperpigmentation is on the facial aspect of gingiva and visible during smile and speech, especially in patients with gummy smiles. Gingival depigmentation has been carried out using surgical, chemical, electrosurgical, and cryosurgical procedures. The two cases presented here show the successful depigmentation using an Er,Cr:YSGG laser, and a short follow-up period (6 months) for repigmentation results.

Materials and Methods: An Er,Cr:YSGG hydrokinetic system laser set at 20 Hz, 1.75 W to 1.5W, with 20% to 40% air and 12% to 5% water spray was used for removal of pigmented gingiva in 2 patients. The pigmented areas were treated in noncontact mode, and both cases were completed during one appointment.

Results: Even though both cases were performed without any anesthesia, no intra-operative or postoperative pain or discomfort appeared. After 24 h, the lased gingiva was partly covered with a thin layer of fibrin, which exfoliated during the first week following treatment. The ablated wound healed almost completely in 1 week.

Conclusion: These results pointed out that YSGG laser is a good and safe choice for removal of pigmented gingiva without local anesthesia. The postoperative period is comfortable for the patient and healing is fast and good. No repigmentation occurred in either patient after 6 months.

Keywords: Er,Cr:YSGG, laser, hyperpigmentation, hydrokinetic system, depigmentation.

J Oral Laser Applications 2005; 5: 249-253.

The color of the gingiva is determined by several factors, including the number and size of blood vessels, epithelial thickness, quantity of keratinization, and pigments within the epithelium. Melanin, carotene, reduced hemoglobin and oxyhemoglobin are the main pigments contributing to the normal color of the oral mucosa.¹ Frequently, gingival hyperpigmentation is caused by excessive melanin deposition mainly located in the basal and suprabasal cell layers of the epithelium.² Melanin is elaborated by specific cells – melanocytes residing in the basal layer – and is transferred to the basal cells where it is stored in the form of melanosomes. It can also be found in keratinocytes of gingival epithelium.³

Melanin hyperpigmented gingiva is an esthetic problem in many individuals, particularly if the hyperpigmentation is on the facial aspect of the gingiva and visible during smile and speech, especially in patients with gummy smiles.² The degree of pigmentation depends on a variety of factors, especially the activity of melanocytes. Fair-skinned individuals are very likely to have nonpigmented gingiva, but in darker skinned persons, the chance of having pigmented gingiva is extremely high. The highest rate of gingival pigmentation has been observed in the area of the incisors. The rate decreases considerably in the posterior regions.⁴

Gingival depigmentation has been carried out using surgical, chemical, electrosurgical, and cryosurgical pro-

cedures.^{2,5} Recently, laser ablation has been recognized as one of the most effective, comfortable, and reliable techniques.⁵ Many laser systems such as Q-switched ruby laser, flash-lamp pumped-dye laser, argon laser, CO₂ laser, Nd:YAG laser, and Er:YAG laser have been used for dermal depigmentation.^{1,2,5}

Er,Cr:YSGG hydrokinetic system laser (YSGG) with a wavelength of 2780 nm, frequency of 20 Hz, pulse energy between 0 and 300 mJ, has FDA (Federal Drug Administration; USA) approval for several soft tissue procedures such as gingivoplasty, gingivectomy, fibroma removal, and granular tissue removal. Since it is just a hard tissue laser working according to hydrokinetic system theory, the focal distance is approximately 1.5 mm away from the tissue. The water droplets coming out of the water spray are energized by the laser energy 1.5 mm from the end of the tip. Thus, the most focused distance while working with YSGG laser is 1.5 mm away from the tissue, so that less thermal damage occurs compared to other hard tissue laser systems. Since air and water percentages can be changed by the operator, less bleeding or less pain can be obtained.⁶

Repigmentation after gingival depigmentation is an important point of which clinicians should be aware. Reports of repigmentation are quite limited and varied.¹

The following cases show successful depigmentation using an Er,Cr:YSGG laser and results regarding repigmentation obtained after a short follow-up period (6 months).

CASE REPORTS

In both cases, an Er,Cr:YSGG (erbium, chromium, yttrium, scandium, gallium, garnet) hydrokinetic system laser (Waterlase, Biolase Technology, San Clemente, CA, USA) was used with the wavelength of 2780 nm, frequency of 20 Hz, and pulse energy between 0 and 300 mJ.

CASE 1

A 22-year-old male with dark skin color complained about his unesthetic gingiva (Fig 1). The pigmented regions were most pronounced in the anterior region, so that he was not happy with his smile and esthetic appearance. The color of the gingiva was dark to black; there were no contributory medical problems. The patient was very fearful of dental injections.

Preoperative pictures were taken and topical anesthetic gel applied to the operation field. In compliance with FDA rules, patient and staff used special eyeglasses for protection. Caution should also be taken near reflective surfaces, since the laser beam may be reflected from dental mirrors or instruments and absorbed by other intraoral regions.⁷

The YSGG laser application started with 600- μ m sapphire tips, 1.5 W, and 20% air/12% water in non-contact mode by a sweeping motion localized only on the pigmented regions. The procedure was performed in a cervico-apical direction on all pigmented areas. After slight removal of the connective tissue, the settings were changed to 1.75 W and 40% air/5% water in order to obtain more rapid ablation with less hemorrhaging and no thermal damage to the tissue.

Every five minutes, the operation field was wiped with sterile gauze soaked in 1% normal saline solution. The depigmentation procedure continued until no pigments remained. The complete treatment was performed in 30 min.

After wiping the operation field for the last time, there was slight bleeding. No periodontal pack or additional material was applied to support the healing procedure. The patient was recalled 4 days later and intraoral pictures were taken (Fig 2).

The patient was instructed to avoid smoking, alcohol, and spicy foods. He was advised to keep his wound area clean by soft brushing for the first week. No analgesic was prescribed.

CASE 2

A 50-year-old female African-American patient presented with broad pigmentation of her maxillary gingiva and moderate pigmentation of her mandibular gingiva (Fig 4). Since she already had experience with YSGG laser therapy from previous endodontic treatment, she wanted to be treated with YSGG laser. The gingival depigmentation procedure was performed as previously described in Case 1. Postoperative instructions were given, no analgesic was prescribed, and the patient was recalled 4 days later, when intraoral pictures were taken (Fig 5).

CLINICAL RESULTS

After 24 h, the lased gingiva was partly covered with a thin layer of fibrin, which exfoliated during the first week following treatment. The ablated wound was

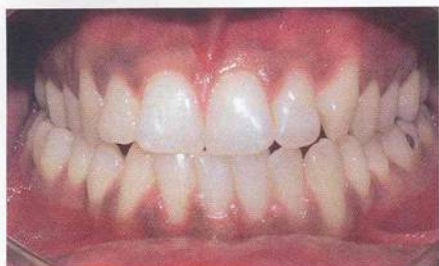

Fig 1 Intraoral preoperative view of case 1. The patient complained about the color of his anterior gingiva.

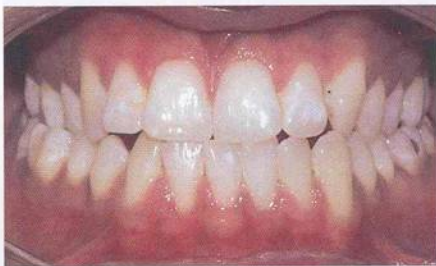

Fig 2 Intraoral 4-day postoperative view of case 1.

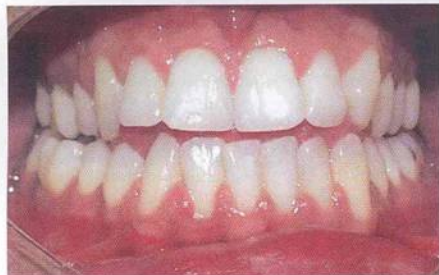

Fig 3 Intraoral 6-month postoperative view of case 1.

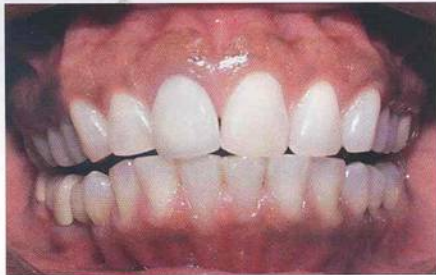

Fig 4 Intraoral preoperative view of case 2. The patient was unhappy with her smile due to the extensive pigmentation of her maxillary gingiva.

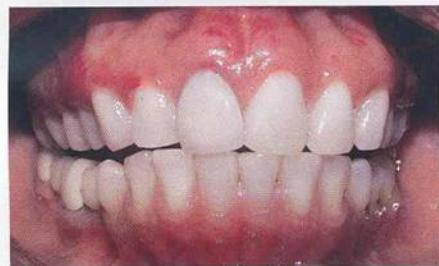

Fig 5 Intraoral 4-day postoperative view of case 2.

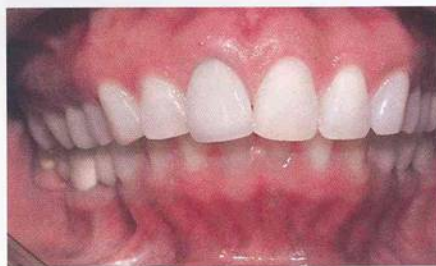

Fig 6 Intraoral 6-month postoperative view of case 2.

healed almost completely in 1 week. The color of ablated gingiva was pink and healthy one week after ablation. The gingiva was similar to the normal untreated gingiva, completely lacking melanin pigmentation. In the second case, a small part of the maxillary gingiva was reddish compared to neighboring untreated gingiva, and was nonkeratinized.

After the treatment procedure, the patients filled out the patient evaluation form. They were asked if they had any pain or discomfort during treatment, and if they would recommend this treatment technique to other patients. In both cases, the answers revealed no pain or discomfort during procedures and patients mentioned that they would recommend this technique.

On the 4th postoperative day, the patients were asked if they had felt any pain or discomfort within the past 4 days. One patient reported slight sensitivity of the maxillary surgical site about 12 hours postoperatively. She did not need any medication, and the sensitivity did not cause any change in regular behaviors. Sensitivity disappeared within 24 h. Patients were recalled 6 months later and intraoral pictures were taken again (Figs 3 and 6).

DISCUSSION

Numerous authors have reported on the use of lasers for soft tissue removal. They include procedures common to oral surgery, oral pathology, restorative dentistry and periodontics.^{8,9} There is abundant evidence confirming markedly less bleeding, particularly of highly vascular oral tissues, with laser surgery. Anecdotal reports that incising oral soft tissue with a laser is less painful than using a scalpel and therefore requires less oral anesthetic have no scientific confirmation to date.¹⁰ In our study, patients were given topical anesthetic gel, but no infiltration anesthesia was used. We observed less bleeding during laser therapy compared to conventional surgical techniques. Postoperative pain from oral and otolaryngological surgical procedures has been claimed to be reduced in laser surgery. It is theorized that this may be due to protein coagulum that is formed on the wound surface, thereby acting as a biological wound dressing^{10,11} and sealing the ends of the sensory nerves.¹² In the present study, patient satisfaction was good. There were no complaints about pain during treatment or postoperatively. Tal et al¹ and Alsawaswan et al² administered local anesthesia, but in their patients, although ablation was deeper, no repeated topical anesthesia was used. Some reports suggest that laser-created wounds heal more quickly and

produce less scar tissue than conventional scalpel surgery.^{13,14} Conversely, other studies have shown the delay of re-epithelization of the laser wound compared with conventional wounds.^{15,16} In our report about depigmentation treatment with Er,Cr:YSGG laser, re-epithelization was completed after 1 week and the gingiva was similar to the normal untreated gingiva.

Repigmentation after depigmentation has been reported following the use of different techniques. The mechanism of repigmentation is not understood, but according to the migration theory, active melanocytes from the adjacent pigmented tissues migrate to treated areas, causing repigmentation.¹⁷

Dummett and Bolden¹⁸ observed partial recurrence of hyperpigmentation in 6 out of 8 patients after gingivectomy at 1 to 4 months, whereas Perlmutter and Tal¹⁷ described partial recurrence after 7 to 8 years. Tal et al¹⁹ and Tal²⁰ did not observe repigmentation until 20 months after cryosurgical depigmentation. No recurrence of hyperpigmentation was found in any of the four patients treated by Atsawasuwan et al² at 11 to 13 months after gingival depigmentation using Nd:YAG laser. Nakamura et al²¹ described depigmentation with CO₂ laser in 10 patients. No repigmentation was seen in the first year, but 4 patients showed repigmentation at 24 months. Tal et al¹ observed no repigmentation occurring in any of the patients treated with Er:YAG laser after 6 months.

In the present study, repigmentation was not observed during a short follow-up period (6 months). However, long-term observations are required to determine the efficacy of YSGG laser in hyperpigmentation treatment.

CONCLUSIONS


Treatment of gingival hyperpigmentation by Er,Cr:YSGG laser radiation in a defocused mode was found to be a safe and effective procedure. Postoperative patient satisfaction in terms of esthetics and pain was excellent. The gingiva healed uneventfully and completely regenerated with no infection, pain, swelling, or scarring. No repigmentation occurred in either patient after 6 months. Based on these observations, Er,Cr:YSGG laser is a good treatment choice for gingival depigmentation.

REFERENCES

1. Tal H, Oegjesser D, Tal M. Gingival depigmentation by Erbium:YAG laser: clinical observations and patient responses. *J Periodontol* 2003;74:1660-1667.
2. Atsawasuwan P, Greethong K, Nimmanon V. Treatment of gingival hyperpigmentation for esthetic purposes by Nd:YAG laser: report of 4 cases. *J Periodontol* 2000;71:315-321.
3. Dummett CO. Oral pigmentation. First symposium on oral pigmentation. *J Periodontol* 1960;31:356-360.
4. Tamizi M, Taheri M. Treatment of severe physiologic gingival pigmentation with free gingival autograft. *Quintessence Int* 1996;27:555-558.
5. Tal H, Oegjesser D, Tal M. Gingival depigmentation for aesthetic purposes using erbium:YAG laser: rationale and technique [in Hebrew]. *Refuat Hapeh Vehashinayim* 2002;19:25-32, 69.
6. FDA Website in <http://www.fda.gov/cdrh/pdf3/k030523.pdf>
7. Nellburger EL, Miserandio L. Laser reflectance: hazard in the dental operatory. *Oral Surg Oral Med Oral Pathol* 1988;66:659-661.
8. Mlida M. Lasers in periodontics. *Periodontol Clin Invest* 1992;14:14-20.
9. Pirk RM, Coluard MD. Current status of laser in soft tissue dental surgery. *J Periodontol* 1993;64:589-602.
10. Cohen ER, Ammons W. Laser in Periodontics (position paper). *J Periodontol* 1996;67:826-830.
11. Rossmann JA, Cobb CM. Lasers in periodontal therapy. *Periodontology* 2000 1995;9:150-164.
12. Schuller DE. Use of the laser in the oral cavity. *Otolaryngol Clin North Am* 1990;23:31-42.
13. Carruth JAS. Resection of the tongue with the carbon dioxide laser. *J Laryngol Otolaryngol* 1982;96:529-543.
14. Fisher SE, Frame JW, Browne RM, Tranter RMD. A comparative histological study of wound healing following CO₂ laser and conventional surgical excision of canine buccal mucosa. *Arch Oral Biol* 1983;28:287-291.
15. Moreno RA, Hebda PA, Zitelli JA, Abell E. Epidermal cell outgrowth from CO₂ laser and scalpel cut explants. *J Dermatol Surg Oncol* 1984;10:863-868.
16. Fisher SE, Frame JW. The effect of the carbon dioxide surgical laser on oral tissues. *Br J Oral Maxillofac Surg* 1984;22:414-425.
17. Perlmutter S, Tal H. Repigmentation of the gingiva following injury. *J Periodontol* 1986;57:48-50.
18. Dummett CO, Bolden TE. Post surgical clinical repigmentation of the gingiva. *Oral Surg Oral Med Oral Pathol*. 1963;16:353-357.
19. Tal H, Landsberg J, Kozlowsky A. Cryosurgical depigmentation of the gingiva: A case report. *J Clin Periodontol* 1987;14:614-617.
20. Tal H. A novel cryosurgical technique for gingival depigmentation. *J Am Acad Dermatol* 1991;24:292-293.
21. Nakamura Y, Hossain M, Hirayama K, Matsumoto K. A clinical study on the removal of gingival melanin pigmentation with the CO₂ laser. *Lasers Surg Med* 1999;25:140-147.

Contact address: G. Berk, Mahatma Gandhi Cad. No:34
06700 G.O.P., Ankara, Turkey. Tel: +90-312-4476090. Fax:
+90-312-4462782. e-mail: gberk@dentaform.com.tr or
nberk@dentaform.com.tr

Breath Malodor: A Step-by-Step Approach



Daniel van Steenberghe

95 pp; 40 color illus;
ISBN 1-85097-104-8;
US \$48/£28/€38

This nicely illustrated pocket guide focuses on the differential diagnosis of breath malodor, also known as halitosis. It provides indications for the step-by-step clinical examination of patients affected by this condition. Since most causes of breath malodor are intraoral, this pocket guide is particularly useful for dentists and periodontists. However, general medical practitioners, ENT specialists, gastroenterologists, and psychiatrists will be interested in the sections on postnasal drip, regurgitation esophagitis, liver insufficiency, imaginary bad breath, etc. Practical therapeutic guidelines are provided on the use of mouthwashes, tongue scrapers, and dentifrices.

Contents

- Glossary
- Introduction
- Patient History
- Patient Questionnaire
- Causes of Breath Malodor
 - Dental, Periodontal, Tongue, ENT, Bronchi and lungs,
 - Gastrointestinal, Liver, Kidney, Systemic metabolic disorders,
 - Medications, Hormonal, Imaginary breath malodor
- Clinical Examination
 - Self-examination, Organoleptic evaluation, Instrument
 - measurements, Oropharyngeal examination, Laryngeal
 - examination, Nasal examination, Sinus examination,
 - Esophageal examination, Blood tests, Gastrointestinal
 - investigations, Imaginary breath malodor
- Treatment
 - Oral pathologies, ENT pathologies, Bronchopulmonary
 - disorders, Esophageal pathologies, Gastrointestinal
 - pathologies, Kidney pathologies, Liver pathologies,
 - Metabolic diseases, Hormonal factors, Imaginary breath
 - malodor
- General Conclusions
- Patients' Stories

To Order

Call: +44 (0) 20 8949 6087

Fax: +44 (0) 20 8336 1484

Website: www.quintpub.co.uk

E-mail: info@quintpub.co.uk



Quintessence Publishing Co Ltd